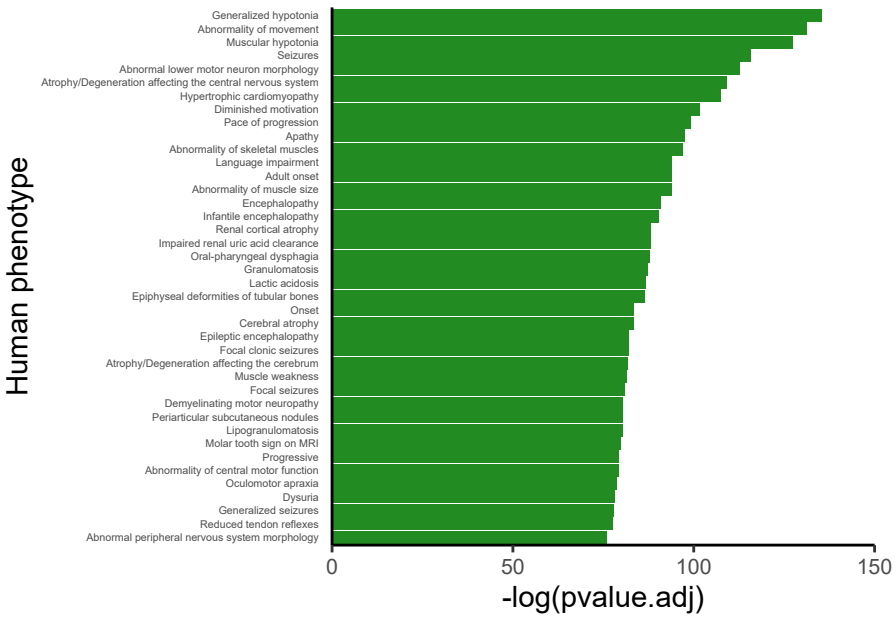
Human phenotype
Generalized hypotonia
Abnormality of movement
Muscular hypotonia
Seizures
Abnormal lower motor neuron morphology
Atrophy/Degeneration affecting the central nervous system
Hypertrophic cardiomyopathy
Diminished motivation
Pace of progression
Apathy
Abnormality of skeletal muscles
Language impairment
Adult onset
Abnormality of muscle size
Encephalopathy
Infantile encephalopathy
Renal cortical atrophy
Impaired renal uric acid clearance
Oral-pharyngeal dysphagia
Granulomatosis
Lactic acidosis
Epiphyseal deformities of tubular bones
Onset
Cerebral atrophy
Epileptic encephalopathy
Focal clonic seizures
Atrophy/Degeneration affecting the cerebrum
Muscle weakness
Focal seizures
Demyelinating motor neuropathy
Periarticular subcutaneous nodules
Lipogranulomatosis
Molar tooth sign on MRI
Progressive
Abnormality of central motor function
Oculomotor apraxia
Dysuria
Generalized seizures
Reduced tendon reflexes
Abnormal peripheral nervous system morphology
0
50
100
150
-log(pvalue.adj)